

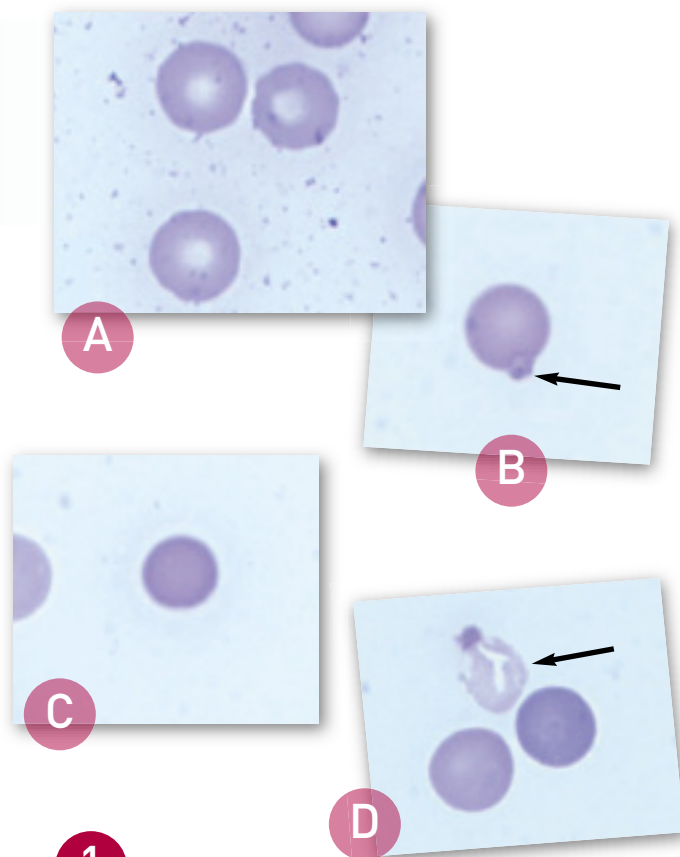
Icterus & Collapse in a Cavalier King Charles Spaniel

A 7-year-old neutered male Cavalier King Charles spaniel is presented after an episode of collapse.

History. The dog was presented to the referring veterinarian after an episode of collapse and weakness at a boarding kennel. The patient had been eating and drinking normally before the collapse episode but had been lethargic. The referring veterinarian noted evidence of hemolytic anemia, which was suspected to be immune-mediated. The dog was referred after initial treatment with vitamin K, gastroprotectants, and IV fluids. An untreated heart murmur was noted on the history.

Physical Examination. On presentation to the referral hospital, the patient had icteric sclera and mucous membranes, a grade 3/6 systolic heart murmur, discomfort on abdominal palpation, nystagmus, and decreased pupillary light responses and mentation.

Laboratory Results. A complete blood count revealed marked neutrophilic leukocytosis with a moderate regenerative left shift, including rare metamyelocytes, toxic change, and monocytosis. Other laboratory findings included a hematocrit of 9%, mild macrocytosis, normal mean corpuscular hemoglobin concentration, increased nucleated red blood cells, and normal platelet count. A review of the blood film revealed 50% to 75% Heinz bodies, numerous spherocytes, and red blood cell ghosts (Figure 1).



1 Normal canine red blood cells (A); large Heinz body (arrow) (B); spherocyte (note the absence of central pallor compared with normal red blood cells) (C); ghost cell with retained Heinz body (arrow) (D)

ASK YOURSELF...

- What potential causes of hemolytic anemia would be consistent with all of the morphologic abnormalities in the erythrocytes?
- What further diagnostic tests are recommended to determine the cause of the hemolysis in this patient?

CONTINUES

**DIAGNOSIS:
PROBABLE ZINC TOXICITY**

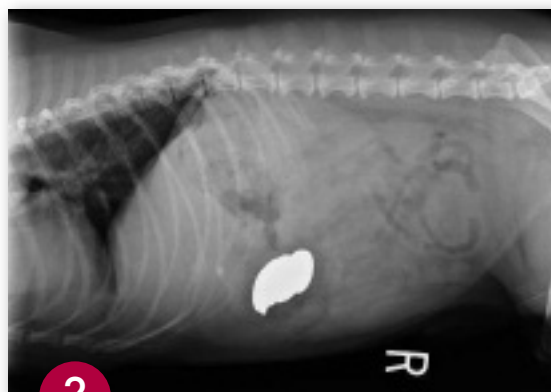Other differential diagnoses could include ingestion of other oxidants, such as acetaminophen, onions, or garlic.

Additional Diagnostics. Abdominal radiography revealed metallic foreign bodies (**Figure 2**) in the stomach. Multiple coins, including some zinc containing pennies minted after 1982, and a medallion were removed endoscopically (**Figure 3**). Blood zinc levels were not measured.

Zinc may directly inhibit coagulation factors in the intrinsic pathway, resulting in prolonged activated partial thromboplastin time with minimal changes in the prothrombin time. Secondary disseminated intravascular coagulation is also possible. In this dog, the prothrombin time was mildly prolonged at 9.2 seconds (normal range, 6.2–7.7 seconds) and the activated partial thromboplastin time was moderately prolonged at 39.5 seconds (normal range, 9.8–14.6 seconds).

Serum biochemical profile abnormalities included azotemia, which may have been prerenal or attributable to zinc-induced renal tubular necrosis, and hyperbilirubinemia with moderately increased alkaline phosphatase and markedly increased alanine and aspartate aminotransferase levels. Liver enzyme abnormalities are very common in dogs with zinc toxicity, and they may be due to direct toxic hepatocellular damage or hemolysis, resulting in hepatic tissue hypoxia. The plasma was also markedly hemolyzed, consistent with an acute hemolytic event.

Treatment. Medical reduction of gastric acid production with histamine-2 receptor antagonists or proton-pump inhibitors may decrease zinc absorption until zinc containing foreign bodies can be removed surgically or endoscopically. Induction of vomiting for removal may not be successful and could worsen mucosal damage to



2 Lateral abdominal radiograph revealing metallic foreign bodies

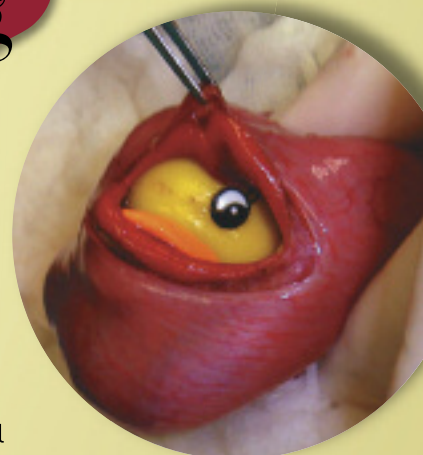

3 Endoscopically removed foreign bodies; note the corroded appearance of the pennies

**WHAT IS THE
strangest thing
YOU'VE EVER FOUND
INSIDE A PATIENT**

We want to see your pictures! Submit a photo and brief story about your strangest find to kelly@cliniciansbrief.com. The winning entry will receive a \$100 gift card and be published, along with the finalists, in *Clinician's Brief*. All pictures and stories will be available on cliniciansbrief.com.

Deadline for submission is September 1, 2010.



CONTINUES

the esophagus and stomach. Chelation therapy has been reported, but no systematic evaluation of benefits has been published in the veterinary medical literature.

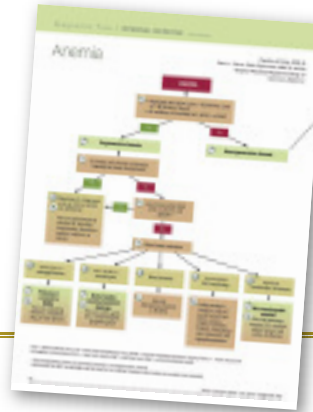Initial stabilization of this patient included fluid therapy to correct dehydration and induce diuresis, and blood products (packed red blood cells and plasma) to ameliorate tissue hypoxia and coagulation abnormalities. The patient also received gastroprotectants.

Outcome. Despite aggressive supportive therapy and removal of the zinc, the patient experienced cardiac and respiratory arrest. Necropsy suggested that disseminated intravascular coagulation was the likely cause of death.

See Aids & Resources, back page, for references and suggested reading.

FIND MORE

See page 56 for a **Diagnostic Tree on Anemia**



? DID YOU ANSWER...

- Causes of Heinz body anemia in the dog include exposure to zinc, *Allium* species (garlic and onion), vitamin K3, and acetaminophen. Causes of spherocytes include immune-mediated damage to erythrocytes, zinc toxicity, and bee and snake envenomation. A few spherocytes may be associated with any cause of Heinz body anemia; however, when large numbers of spherocytes and Heinz bodies are present simultaneously, zinc toxicity is an important differential diagnosis. Heinz bodies are considered the primary indicator because spherocytes are present in only a minority of cases.
- Further diagnostic tests should include chest and abdominal radiography to evaluate the patient for the presence of metallic foreign bodies in the esophagus, stomach, or gastrointestinal tract, along with evaluation of blood zinc levels. The result of a Coombs test may be positive in patients with zinc toxicity, and it does not distinguish this condition from idiopathic immune-mediated hemolytic anemia.

PRACTICE HOTLINE

NEW DENTAL IMAGING PRODUCT



Dental Focus, LLC (dentalfocus.biz) released the new SopiX₂ Digital Imaging System. This system's patented technology makes it possible to control the amount of x-rays accumulated by the sensor, protecting each image from overexposure and ensuring that all images are optimal. Pathology, such as tooth resorption detail and bone trabeculation, are clearly visible and the ability to see through

the zygomatic arch is now possible. For more information, call 908-230-1955 or visit Dental Focus' website.—*Press release 7/2010*

HILL'S ADDS NEW "INGREDIENT"

Hill's Pet Nutrition, Inc has added a new "ingredient" to Prescription Diet d/d Feline dry pet food formulas—improved palatability through better taste and aroma. "My own cats love the improved d/d Feline formulas and

I know they are healthier because of it," says Marty Greer, DVM, coowner of Veterinary Village, LLC. In addition, some of the key Prescription Diet pet food products have a new lower price to make following veterinary recommendations more affordable for pet owners. For more information, visit hillsvet.com.—*Press release 5/2010*

AAHA DEVELOPS DIABETES GUIDELINES

The American Animal Hospital Association has created the *AAHA Diabetes Management Guidelines for Dogs and Cats* with the help of an educational grant from Intervet/Schering-Plough Animal Health (intervet.com). This new set of guidelines covers several topics on diabetes including initial treatment and monitoring, home monitoring, diagnostic testing, and using diet therapy to manage diabetes in pets. A PDF of the guidelines is available online at aahanet.org. For more information about AAHA or the diabetes guidelines, contact Jason Merrihew at 720-963-4479 or jason.merrihew@aahanet.org.—*Press release 6/2010*